



# THE MERCK VETERINARY MANUAL



> SEE ALL MERCK MANUALS

SEARCH



**Merck Manual > Veterinary Professionals > Generalized Conditions > Equine Viral Arteritis**

These search terms have been highlighted Equine Piroplasmiasis

## Overview of Equine Viral Arteritis

(Epizootic cellulitis-pinkeye, Equine typhoid, Rotlaufseuche)

Equine viral arteritis (EVA) is an acute, contagious, viral disease of equids **caused by equine arteritis virus (EAV)**. Typical cases are characterized by **fever, depression, anorexia, leukopenia, dependent edema (especially of the lower hind extremities, scrotum, and prepuce in the stallion), conjunctivitis, supra- or periorbital edema, nasal discharge, respiratory distress, skin rash, temporary subfertility in affected stallions, abortion, and infrequently, illness and death in young foals.** A variable percentage of postpubertal colts and **stallions become carriers and semen shedders** after infection with EAV.

### Etiology and Pathogenesis

EAV is a small, enveloped single-stranded positive-sense RNA virus

and the prototype virus of the genus *Arterivirus*, family Arteriviridae, order Nidovirales. It has 10 open reading frames (ORFs), of which ORFs 2a, 2b, 3, 4, 5, 5a, 6, and 7 encode the viral structural proteins. EAV is one of the three most important equine viral respiratory pathogens. The virus is not especially resistant outside the body, and survival  $\geq 37^{\circ}\text{C}$  can be short-lived. In contrast, EAV can maintain infectivity in tissues or bodily fluids for extended periods at storage temperatures equal to or below freezing. It can remain viable in frozen semen for many years.

Although only one major serotype of EAV has so far been identified, the prototype Bucyrus strain, genomic and antigenic variation exists among temporally and geographically different isolates. Pathogenicity also varies among viral strains, with some capable of causing moderate to severe signs of disease whereas others only induce a fever.

After respiratory exposure, EAV invades the upper and lower respiratory tract and multiplies in nasopharyngeal epithelium and tonsillar tissue and in bronchial and alveolar macrophages. Infected cells of the monocytic lineage and CD3<sup>+</sup> T lymphocytes transport the virus to the regional lymph nodes, where it undergoes a further cycle of replication before being released into the bloodstream. The cell-associated viremia that follows ensures dissemination of EAV throughout the body. By day 6–8, the virus localizes in the vascular endothelium and medial myocytes of the smaller blood vessels, especially the arterioles, and causes a panvasculitis. It can also be

found in the epithelium of certain tissues, particularly the adrenals, seminiferous tubules, thyroid, and liver. Vascular lesions include endothelial swelling and degeneration, neutrophilic infiltration, and necrosis of the tunica media of affected vessels. These lesions give rise to edema and hemorrhage, which are believed to result from activation of the proinflammatory cytokines IL-1 beta, IL-6, IL-8, and possibly TNF- $\alpha$ . Maximal vascular injury occurs by about day 10, after which lesions begin to resolve.

Based on experimental infection of pregnant mares with the experimentally derived highly virulent Bucyrus strain of EAV, abortion is believed to result from a myometritis that gives rise to impairment of the placental circulation and death of the fetus. However, this is unlikely to represent the pathogenesis of abortion in naturally acquired cases of EAV infection, which has yet to be determined.

Except in certain infected stallions that become carriers of the virus, EAV is no longer detectable in tissues and body fluids beyond day 28 after primary infection. However, stallions that remain persistently infected harbor the virus principally in certain accessory sex glands, especially the ampulla of the vas deferens, where it can remain for many years. Some carrier stallions may shed EAV from their reproductive tracts for an extended period.

## **Epidemiology and Transmission**

While the natural and experimental host range of EAV is restricted

principally to equids, there are very limited data to suggest the virus may also infect alpacas and llamas. There is no evidence that EAV is transmissible to people. Based on serologic surveys and reported outbreaks of equine viral arteritis, EAV is present in equine populations in many countries worldwide, with the notable exceptions of Japan and Iceland. The prevalence of infection varies widely both between countries and among breeds in the same country. It is frequently highest in Standardbreds and Warmbloods. Despite the widespread global distribution of EAV, laboratory-confirmed outbreaks of EVA are relatively uncommon. However, this situation appears to be changing in more recent years, with an increase in the number of verified occurrences of the disease being reported. A major factor contributing to this change is the continued growth in the volume of international trade in horses and equine semen.

The epidemiology of EVA involves virus-, host-, and environment-related factors, including variability in pathogenicity among naturally occurring strains of the virus, modes of transmission, occurrence of the carrier state in stallions, and the nature of acquired immunity to infection. Outbreaks of EVA are most often linked to the movement of infected animals or the shipment of virus-contaminated semen. Frequently, viral transmission occurs with minimal if any detectable clinical signs in acutely infected equids.

Transmission of EAV can occur by respiratory, venereal, and congenital routes or by indirect means. Spread by the respiratory route is the principal mode of dissemination of the virus during the acute

phase of infection. It is primarily responsible for transmission of EAV among naive equids kept in close contact (eg, at racetracks, shows, sales, veterinary hospitals, and under conditions of intensive management on breeding farms). EAV can also be transmitted venereally by the acutely infected mare and by the acutely or chronically infected stallion. Mares can be readily infected by the venereal route after breeding to a carrier stallion either by live cover or artificial insemination with fresh-cooled or cryopreserved semen. There is evidence that EAV can be spread through embryo transfer. Infection can also be spread through indirect contact with virus-contaminated fomites (eg, breeding shed equipment, shanks, or twitches) or on the hands or apparel of animal handlers.

**The carrier state has been confirmed** in sexually mature intact males, specifically postpubertal colts and stallions, but not in mares, geldings, sexually immature colts, or fillies. Establishment and persistence of EAV in the reproductive tract of stallions is testosterone-dependent. The carrier stallion is the natural reservoir of EAV and is responsible for its dissemination and persistence in equine populations. Frequency of the carrier state can vary from <10% to >70%. There is evidence that stallions with CD3<sup>+</sup> T lymphocytes that are susceptible to EAV infection are at higher risk of becoming carriers than stallions with the CD3<sup>+</sup> T lymphocyte-resistant phenotype. Persistently infected stallions shed EAV constantly in the sperm-rich fraction of the semen but not in any other secretions or excretions. Duration of the carrier state can range from weeks to many years. Persistent EAV infection clears

spontaneously in a variable percentage of stallions, with no evidence of subsequent reversion to a shedding state. Existence of the carrier state does not appear to impair the fertility of infected stallions nor otherwise adversely affect their clinical condition. Carrier stallions also serve as the principal means by which genetic diversification of EAV can occur, with potential emergence of novel viral variants.

Compared with other equine respiratory viruses, EAV stimulates a stronger, longer-lasting immunity that is protective against development of clinical disease, including abortion and establishment of the carrier state in stallions. High levels of neutralizing antibodies that frequently persist for at least 2–3 yr can be stimulated by natural exposure to the virus and by vaccination.

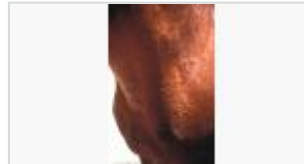
## Clinical Findings

Exposure to EAV may result in clinical or asymptomatic infection, depending on the relative pathogenicity of the virus strain involved, viral dose, age and physical condition of the animal, and various environmental factors. Most cases of primary infection are asymptomatic. Onset of the acute phase of EAV infection, whether associated with clinical signs or not, is preceded by an incubation period of 3–14 days, which varies mainly with the route of exposure. The interval is usually 6–8 days after venereal transmission of the virus. Clinical signs can differ in range and severity between disease outbreaks and between affected individuals in the same outbreak. Any combination of the following may be seen: fever lasting 2–9 days,

leukopenia, depression, anorexia, limb edema (especially of the lower hindlimbs), and edema of the scrotum and prepuce. Less frequently encountered signs include conjunctivitis, lacrimation and photophobia, periorbital or supraorbital edema, rhinitis and nasal discharge, edema of the ventral body wall (including the mammary glands of mares), an urticarial-type skin reaction (often localized to the sides of the face, neck, or over the pectoral region, although it can be generalized), stiffness of gait, dyspnea, petechiation of mucous membranes, diarrhea, icterus, and ataxia.

Strains of EAV can cause abortion throughout much of pregnancy (3 mo to more than 10 mo). Abortion may occur late in the acute phase or early in the convalescent phase of the infection, with or without prior clinical signs of EVA. In natural outbreaks, abortion rates can vary from <10% to as high as 60%. There is no evidence confirming that mares bred with EAV-infective semen will abort later in gestation. Mares that abort from the virus are already pregnant at time of exposure; this occurs primarily by the respiratory route through direct proximity with an acutely infected animal. Abortion occurs 1–4 wk later. Mares exposed very late in gestation may not abort but give birth to a foal congenitally infected with the virus. Mares that abort from EAV infection have not been proved to be less

Equine viral arteritis, skin reaction



Equine viral arteritis, lacrimation



Equine viral arteritis, periorbital edema



Equine viral arteritis, scrotal edema

fertile.

Stallions with EVA may undergo a period of short-term subfertility. This has been observed in individuals that develop a high and prolonged fever and extensive scrotal edema. Affected stallions may exhibit reduced libido associated with decreases in total and progressively motile sperm, curvilinear velocity, percentage of live spermatozoa, and percentage of morphologically normal spermatozoa. The changes in semen quality are believed to result from increased intratesticular temperature and not from the direct effect of EAV on spermatogenesis and testicular function. There is strong evidence that fever and scrotal edema exert independent effects on semen quality. Semen changes can last for 14–16 wk before returning to normal. No longterm adverse effects on fertility have been seen in fully recovered stallions.



The frequency and severity of clinical illness associated with EAV infection tend to be greater in very young, old, or debilitated individuals and under adverse climatic conditions. Regardless of severity of clinical signs, affected horses invariably make complete recoveries, even in the absence of symptomatic treatment. Mortality in older horses is very rarely encountered in natural outbreaks. However, it can occur in neonatal and in young foals up to a few months of age that succumb from a fulminating pneumonia or pneumoenteritis.

### ***Lesions:***

The gross and microscopic lesions in fatal cases of EVA reflect the



extensive and considerable vascular damage caused by the virus; these descriptions are primarily based on experimental infection with the highly pathogenic Bucyrus strain of EAV. The most significant gross findings include edema, congestion, and hemorrhages, especially in the subcutis of the limbs and abdomen; excess peritoneal, pleural, and pericardial fluid; and edema and hemorrhage of the intra-abdominal and thoracic lymph nodes and of the small and large intestine, especially the cecum and colon. Pulmonary edema, emphysema and interstitial pneumonia, enteritis, and infarcts in the spleen have been reported in naturally acquired fatal cases of the disease in foals.

Aborted fetuses are often partly autolyzed. Gross lesions are usually absent; if present, they are limited to an excess of fluid in body cavities and a variable degree of interlobular pulmonary edema. The vascular damage and immune-mediated lesions seen in older animals are seldom found in infected fetuses.

The characteristic microscopic lesion seen in cases of EAV infection is a vasculitis, involving primarily smaller arterioles and venules. Histologically, changes can range from vascular and perivascular edema, with occasional lymphocytic infiltration and endothelial cell hypertrophy in mild cases, to fibrinoid necrosis of the tunica media, extensive lymphocytic infiltration, necrosis and loss of endothelium, and thrombus formation in severe cases. Microscopic lesions are frequently not seen in cases of abortion. If present, vasculitis has been seen in the placenta and the brain, liver, spleen, and lungs of the fetus.

Fatal cases of EAV infection in young foals are characterized by interlobular edema, congestion and mononuclear cell infiltration in the lungs, and lymphoid depletion and hemorrhage in lymphoreticular tissues. Focal hemorrhages and necrosis of the intestinal mucosa have been described when there is an associated enteritis.

## Diagnosis

The symptomatology of EVA can mimic that of a range of other respiratory and nonrespiratory equine diseases. Accordingly, laboratory examination of appropriate specimens is essential to confirm diagnosis. Equine influenza, equine herpesvirus 1 and 4–related diseases, infection with equine rhinitis A and B viruses or equine adenoviruses, and purpura hemorrhagica are among the more common equine illnesses that clinically resemble EVA. The latter must also be differentiated from equine infectious anemia, toxicosis caused by hoary alyssum (*Berteroa incana*), and allergy-induced urticaria. Several foreign diseases that should be considered in a differential diagnosis of EVA include Getah virus infection, dourine, and African horse sickness fever (see [African Horse Sickness](#)).

Abortion caused by EAV must be differentiated from that due to equine herpesvirus 1 or 4. A helpful but not always reliable distinguishing feature is that mares that abort because of EAV may display prior clinical signs of EVA, whereas mares that abort because of equine herpesvirus seldom exhibit any premonitory clinical evidence of infection. Furthermore, EAV-infected fetuses not infrequently are

somewhat autolyzed at time of expulsion and very often are devoid of any gross and even microscopic lesions. In contrast, herpesvirus-infected fetuses are invariably fresh and usually display characteristic gross and microscopic lesions.

Laboratory confirmation of a provisional clinical diagnosis of EVA should be pursued without delay in suspected outbreaks. This can be based on virus isolation, detection of viral nucleic acid, visualization of viral antigen by immunohistochemical examination, or demonstration of a recent humoral antibody response by testing paired (acute and convalescent) sera collected 3–4 wk apart.

The most appropriate samples for virus isolation and/or detection of viral nucleic acid by reverse transcriptase-PCR (RT-PCR) are nasopharyngeal swabs or washings and unclotted (citrate or EDTA) blood samples. To optimize the chances of isolation or detection, samples should be collected as early as possible after the onset of clinical signs or suspicion of EAV infection. After collection, swabs should be transferred directly into viral transport medium and shipped refrigerated or frozen in an insulated container via an overnight delivery service to a laboratory capable of testing for this infection. Unclotted blood samples should be transported refrigerated but not frozen.

In suspect cases of EAV-related abortion, virus detection should be attempted from placental tissues and fluids and from fetal lung, liver, lymphoreticular tissues (especially thymus), and peritoneal or pleural

fluid. Chorioallantoic membrane and fetal lung are the tissues of choice for recovery of virus. When EAV is suspected in deaths of young foals or older horses, a wide range of tissue specimens, especially the lymphatic glands in the thoracic and abdominal cavities and related organs, should be collected and submitted for laboratory examination, including histologic and immunohistochemical testing.

Detection of the carrier state in a stallion is based initially on determination of the individual's serologic status for EAV. In the absence of a certified history of vaccination, stallions with a serum neutralizing antibody titer  $\geq 1:4$  should be considered potential carriers of the virus until proven otherwise, based on an absence of detectable EAV in their semen. Confirmation of the carrier state is based on demonstration of virus in a semen sample containing the sperm-rich fraction of the ejaculate either by isolation of virus in cell culture or its detection by RT-PCR. Under controlled laboratory conditions, sensitivity of virus isolation and real-time RT-PCR are essentially equivalent for detection of EAV in stallion semen; however, the RT-PCR assay has the advantage of providing a more rapid result. The carrier state can also be determined by test breeding a stallion to two seronegative mares and checking the mares for seroconversion 28 days after breeding.

Of the serologic assays evaluated for detection of antibodies to EAV, the complement-enhanced virus neutralization test continues to be the most reliable for the diagnosis of acute EAV infection and for seroprevalence studies. A number of ELISA tests have been

developed, only a few of which offer comparable but not equivalent sensitivity and specificity. None of the available serologic tests can differentiate antibody titers resulting from natural infection from those due to vaccination.

## Treatment, Prevention, and Control

There is no specific antiviral treatment currently available for EVA. Aside from young foals, virtually all naturally affected horses make complete clinical recoveries. Symptomatic treatment (eg, antipyretic, anti-inflammatory, and diuretic drugs) is indicated only in severe cases, especially in stallions. Prompt symptomatic treatment of stallions with a high or prolonged fever and significant scrotal and preputial edema can reduce the likelihood of short-term subfertility. **Good nursing care, adequate rest, and a gradual return to normal activity are indicated.** There is no effective treatment for EVA-related cases of pneumonia or pneumoenteritis in foals. Because congenitally infected foals are very productive sources of EAV and their chances of survival are essentially nil, early euthanasia should be considered to minimize the risk of further spread of the virus to any susceptible contacts, especially pregnant mares and young foals. Although there is some evidence that temporary down-regulation of circulating testosterone by GnRH immunization or through the use of a GnRH antagonist promotes clearance of EAV from the reproductive tract of carrier stallions, neither strategy has yet been adequately validated.

**EVA is a manageable and preventable disease that can be controlled**

by observance of sound management practices together with a targeted vaccination program. Only one commercial vaccine, a modified-live virus product, is currently available in North America. The vaccine protects against development of EVA, including abortion, and establishment of the carrier state in stallions. While the vaccine is safe and immunogenic for stallions and nonpregnant mares, the manufacturers do not recommend its use in pregnant mares, especially in the final 2 mo of gestation or in foals <6 wk of age, unless under circumstances of high risk of exposure to natural infection. Experimental and field studies have shown that there are no adverse consequences to vaccinating pregnant mares up to 3 mo before foaling and during the immediate postpartum period. However, there is a low risk of abortion in mares vaccinated during the last 2–3 mo of pregnancy. Minimizing or eliminating direct or indirect contact of unprotected horses with infected animals or with virus-infective semen is critical to the success of any prevention program.

The primary focus of current control programs is to restrict the spread of EAV in breeding populations and to reduce the risk of outbreaks of virus-related abortion, death in young foals, and establishment of the carrier state in stallions and postpubertal colts. Although EAV has occasionally been responsible for extensive outbreaks of disease at racetracks, shows, sales, and veterinary hospitals, these have been so sporadic that no specific control programs have been developed to prevent such occurrences.

Effective control programs are predicated on observance of sound

management practices similar to those recommended for other respiratory infections. These include isolation of new arrivals on a premises for 3–4 wk before allowing them to co-mingle with the resident equine population, maintenance of pregnant mares in small isolated groups, identification of carrier stallions, annual immunization of noncarrier breeding stallion populations, and vaccination of colts at 6–12 mo of age to minimize their risk of becoming carriers later in life. Carrier stallions should be managed separately and bred only to naturally seropositive mares or mares vaccinated against EVA. Because fresh-cooled or frozen semen can be an important source of EAV, it should be tested by a laboratory with appropriate diagnostic expertise to confirm its negative EAV status, especially if imported. When breeding a mare artificially with virus-infective semen, the same precautions apply as if breeding by live cover to a carrier stallion.

In the event of a suspected outbreak of EVA, relevant animal health authorities should be promptly notified, with affected and in-contact horses isolated, and restrictions immediately imposed on movement of horses onto and off the affected premises. Appropriate specimens should be collected as soon as possible after onset of clinical signs and submitted for laboratory confirmation of a diagnosis of EVA. Breeding activity should be suspended on breeding farms to minimize risk of further spread of the infection. Stalls and equipment that might have come in contact with infected animals should be thoroughly sanitized. Vaccination of the at-risk equine population on a premises should be seriously considered as a means of restricting further transmission of EAV and of expediting control and resolution of an

outbreak. Movement restrictions should not be lifted until at least 3 wk after the last clinical or suspected case of EVA or laboratory-confirmed case of EAV infection.

Last full review/revision May 2013 by Peter J. Timoney, MVB (Hons), MS, PhD,  
FRCVS

[Audio](#) [Figures](#) [Photographs](#) [Sidebars](#) [Tables](#) [Videos](#)

Copyright © 2009-2015 Merck Sharp & Dohme Corp., a subsidiary of Merck & Co., Inc., Kenilworth, N.J., U.S.A. [Privacy](#) [Terms of Use](#) [Permissions](#)